Photodiagnosis and Photodynamic Therapy 26 (2019) 124–130

Contents lists available at ScienceDirect

Photodiagnosis and Photodynamic Therapy

journal homepage: www.elsevier.com/locate/pdpdt

Influence of antimicrobial photodynamic therapy in carious lesion. Randomized split-mouth clinical trial in primary molars

Luísa Valente Gotardo Lara Alves[a], Fabiana Almeida Curylofo-Zotti[a], Maria Cristina Borsatto[b], Sérgio Luiz de Souza Salvador[c], Rodrigo Alexandre Valério[b], Aline Evangelista Souza-Gabriel[a], Silmara Aparecida Milori Corona[a,*]

[a] Department of Restorative Dentistry, Ribeirão Preto School of Dentistry, University of São Paulo, Brazil
[b] Department of Pediatric Dentistry, Ribeirão Preto School of Dentistry, University of São Paulo, Brazil
[c] Department of Clinical Toxicology and Bromatology of the School of Pharmaceutical Sciences of Ribeirão Preto, University of São Paulo, Brazil

ARTICLE INFO

Keywords:
Dentin
Dental caries
Microbiology
Methylene blue
Clinical trial

ABSTRACT

Background: The literature presents many studies regarding photodynamic antimicrobial therapy (aPDT). However, the great variety of protocols to be used can directly influence its effectiveness in reducing microorganisms. The aim of this randomized split-mouth clinical study was to evaluate the effect of aPDT in the reduction of *Streptococcus mutans* and their effect on restorations performed.
Methods: Twenty children between 6 and 8 years old with active caries and dentin cavitation, located on the occlusal surface of homologous primary molars were included. The selective removal of carious tissue was performed in both molars, than one was subsequently restored and the other received aPDT treatment on the affected dentin with low intensity laser (InGaAlP) associated to 0.005% methylene blue photosensitizer before restoration. Dentin collections were performed only in the tooth submitted to aPDT in three moments: before and after selective caries removal and after application of aPDT. The restorations were analyzed after polishing and after 6 months using *United States Public Health Service* (USPHS) method. Data were analyzed using ANOVA with repeated measures and Bonferroni post-hoc test with a significance level of 5%.
Results: There was a significant reduction on the amount of microorganisms after selective caries removal ($p = 0.04$) and also after the application of aPDT ($p = 0.01$). The reduction of *S. mutans* CFU was of 76.4% after caries removal, but associated with aPDT was 92.6%. After 6 months of clinical evaluation, no difference between groups was found for retention, marginal adaptation, color, marginal discoloration, and secondary caries.
Conclusions: aPDT can be used as an additional treatment against cariogenic microorganisms after selective caries removal without compromising composite resin restorations.

1. Introduction

Dental caries is the most prevalent oral disease worldwide and arises as a result of the dental biofilm [1,2] of which *Streptococcus mutans* comprises 70% of the present bacteria [3]. The major structural component of dental biofilm is the insoluble extracellular polysaccharides (IEPS) [4], and their relationship with dental caries is well established [5–7]. IEPS alters the diffusion properties of the dental plaque [8], enhancing substrate penetration and acid production within the biofilm. Other *S. mutans* virulence properties include the storage of intracellular polysaccharide (IPS), which can be used by the bacteria as a source of carbohydrate for fermentation upon nutrient depletion, prolonging acid production and contributing to caries development [9].

Minimally Invasive Dentistry is a concept with a philosophical profile that integrates prevention, remineralization, and minimal intervention when placing restorations, with the aim of using minimally invasive surgical approaches, and maintaining healthy dental tissues as much as possible [10]. Thus, the selective caries removal technique has shown to be an advantageous alternative for restorative treatment in primary teeth. The approach inactivates caries lesions and reduces the

* Corresponding author at: Department of Restorative Dentistry, School of Dentistry of Ribeirão Preto, University of São Paulo, Avenida do Café, S/ No, Ribeirão Preto, S.P., 14040-904, Brazil.
E-mail addresses: luisavalente_@hotmail.com (L.V.G.L. Alves), fabianacurylofo@gmail.com (F.A. Curylofo-Zotti), borsatto@forp.usp.br (M.C. Borsatto), sldssalv@usp.br (S.L.d.S. Salvador), roavalerio@hotmail.com (R.A. Valério), aline.gabriel@forp.usp.br (A.E. Souza-Gabriel), silmaracorona@forp.usp.br (S.A.M. Corona).

https://doi.org/10.1016/j.pdpdt.2019.02.018
Received 14 November 2018; Received in revised form 15 February 2019; Accepted 22 February 2019
Available online 23 February 2019
1572-1000/ © 2019 Elsevier B.V. All rights reserved.

levels of cariogenic microorganisms in the tissue while reducing the risk of pulp exposure and preventing the progression of cariogenic activity [11,12].

However, considering the limitations of complete and partial caries removal in eliminating bacteria [13], the efficacy of antimicrobial photodynamic therapy (aPDT) as a supplementary step in the treatment of deep carious lesions has been investigated, since there is difficulty in completely removing of caries lesion by conventional methods [13]. Studies have shown that any immediate bacterial reduction can increase the chances of treatment success [14].

Blue photosensitizers, especially toluidine blue and methylene blue, used with a 632.8 nm wavelength laser have shown significant results in terms of reducing several *in vivo* bacterial and fungi cultures [15]. Thus, antimicrobial PDT may be a promising alternative for elimination of the microorganisms in the remaining dentin, increasing the chances of a successful treatment [16]. Other aPDT benefits include its fast action, eliminating bacteria in seconds or minutes, and the unlikely development of resistance in the target bacteria, while preventing damage to neighboring tissues and disturbance of the normal microflora [17].

Considering that aPDT is a noninvasive, safe, cost-effective, and simple technique [18], the present study aimed to analyze its effect using the InGaAlP laser with a 660 nm wavelength, combined with the 0.005% methylene blue photosensitizer on *S. mutans* reduction in caries lesion. In addition, we analyzed restoration outcomes, through a careful analysis using the modified USPHS criteria.

The null hypothesis of this clinical study was that restorations of teeth submitted to aPDT do not have different outcomes than restorations of teeth not submitted to aPDT. The assessed outcomes were retention, marginal discoloration, marginal adaptation, color, and secondary caries. The study also tested the hypothesis that aPDT does not promote an additional bacterial reduction after selective caries removal.

2. Material and methods

2.1. Experimental design

This was a randomized split-mouth clinical trial involving 20 children with active caries lesions on the occlusal surface (class I) of homologous primary molars. The response variables were 1) *S. mutans* colony forming units (CFU) counts at baseline (before caries removal), after caries removal and after aPDT treatment. 2) Clinical analysis of the restorations (with and without aPDT) at baseline (after final polishing) and after 6 months using the modified USPHS criteria.

2.2. Ethical aspects

The study was approved by the Research Ethics Committee of FORP-USP (CAAE: 61188916.8.0000.5419) and registered in the Brazilian Registry of Clinical Trials (Nº UTN: U1111-1208-8835). The children's parents or guardians were informed about the purpose of the study and its implications and signed the consent form agreeing to participate in the research.

2.3. Sample selection

To determine the sample size of the clinical analysis of the restorations, a sample calculation website (www.sealedenvelope.com) was used with the power calculation function and the following parameters: $\alpha = 5\%$, power 90%, success of the control and experimental groups of 98%, and limit of equivalence of 15%, reaching a sample size of 19 restorations per group. Considering the probability of losing some patient, n = 20 was established [19].

The sample size of aPDT' s antibacterial effect study was based on a previous study that evaluated the antimicrobial effect of photodynamic therapy in carious lesions in vivo, considering 5% as to the maximum desirable error; a sample size of 9 was obtained. Considering the probability of losing some sample, n = 10 was established [20].

A total of 3.265 children of both genders aged between 6 and 8 years were examined. The children were selected in the Pediatric Dentistry Clinic of the Ribeirão Preto School of Dentistry, University of Sao Paulo and in public schools in the city of Ribeirão Preto, SP, Brazil. Clinical examinations were performed under adequate lighting followed by radiographic examination using the digital radiography sensor (CDR Elite, Fona, São Paulo, SP, Brazil) with a positioner.

The inclusion criteria were presence of at least two homologous deciduous molars with pulp vitality, active caries lesions with dentin cavitation, and located on the occlusal surface. The exclusion criteria were children who had teeth with spontaneous pain or sensitivity, fistula, edema, mobility not compatible with root resorption stage, and presence of radiolucency in the furcation and periapical region, increased periodontal space, and internal or external dental resorption on radiographic examination.

Ninety-one children were selected, 55 of which refused to participate and 14 were excluded based on the study criteria, totaling 22 children. One child did not return after 6 months for longitudinal follow up and another one had exfoliated both selected teeth, with 20 participants (13 girls and 7 boys) remaining for the final analysis. The CONSORT guide [21] for randomized clinical trials was followed for the study design (Fig. 1).

2.4. Preliminary procedures

Children received dental prophylaxis, individual oral hygiene instructions, and topical application of fluoride. The teeth that needed treatment and were not selected for the study were subsequently treated.

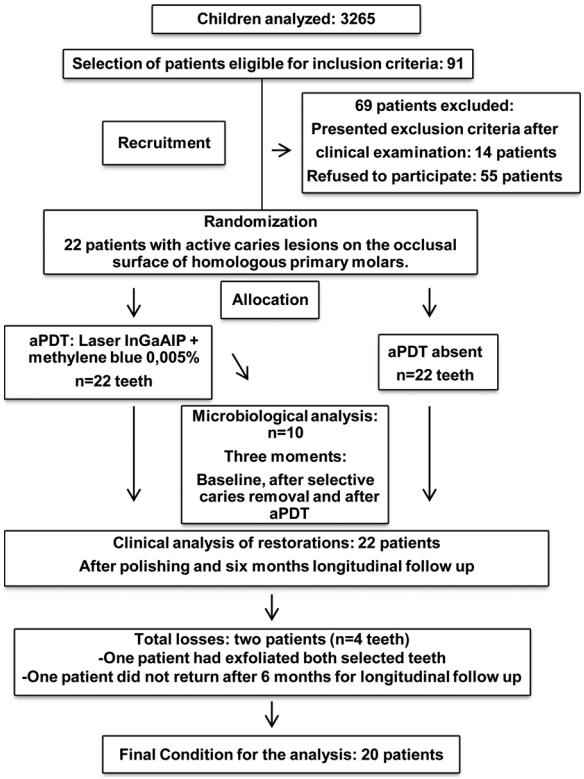

Fig. 1. CONSORT diagram, form of recruitment, allocation, follow-up and analysis of research subjects.

2.5. Microbiological analysis of caries lesion (baseline)

Subject randomization was conducted using a computer spreadsheet. With the aid of a random number generator available at Sealed Envelope Ltd. website, the selected children had their names numbered for treatment order. Teeth were randomly distributed between the groups (with aPDT and without aPDT) by coin toss.

Three dentin collections were performed in the molars receiving aPDT: before treatment, after selective caries removal, and after aPDT treatment.

The topical anesthetic EMLA (Astrazeneca Laboratory, Cotia SP, Brazil) was applied in the mucosa and in the gingival papillae using a cotton swab (Cotonete®, Johnson & Johnson, São José dos Campos, SP). Local anesthetic injection with 2% mepivacaine associated with epinephrine 1: 100,000 was done and the color of the composite resin (Z350; 3 M ESPE, São Paulo, SP, Brazil) was selected based on the natural shade of the tooth using a Vita 3D color scale (Wilcos do Brasil Indústria e Comércio Ltda, Petrópolis, RJ, Brazil). The operative field was isolated with rubber dam (Madeitex, São José dos Campos, SP, Brazil) and clamps (Duflex, SSWhite, Rio de Janeiro, RJ, Brazil), which were selected individually for each tooth.

Before selective caries removal, the carious dentin was collected with sterile curettes # 11, # 11½, and # 12 (Duflex, SSWhite, Juiz de Fora, MG, Brazil). Thus, at least 3 mg of residual dentin was weighed to ± 0.01 mg (Analytical Plus AP 250D, OhausCorp, Florham Park, New Jersey, USA) in sterile microtubes suspended in 1 mL of 0.9% NaCl solution and sonicated at a 20% amplitude for 15 s using a sonic dismembrator (CL-334 Digital Fischer Scientific Sonicator, Park Lane, Pittsburgh, USA). A 50 mL aliquot of the sonicated suspension was diluted in 0.9% NaCl and serial decimal dilutions were inoculated in duplicate using the counting drop technique in a culture media containing SB20, 0.2 U/mL bacitracin, and 15% sucrose (MSB) for *S. mutans*. The plates were incubated in 10% CO_2 at 37 °C for 48 h. The CFUs were counted and the results reported as CFU/mg residual dentin.

2.6. Selective removal of carious tissue

After baseline collection, the selective removal of caries was performed as follows: enamel was removed to create access to the lesion using spherical diamond burs compatible with cavity size (KG Sorensen, Barueri, SP, Brazil) at high speed (Contra-angle handpiece 1: 5 L microseries, Gnatus, Ribeirão Preto, SP, Brazil); selective removal of caries was done using spherical carbide burs #1/2, #1, and #2 (KG Sorensen, Barueri, SP, Brazil) compatible with cavity size in low-speed handpiece (Contra-angle 1: 1 L micro-series, Gnatus, Ribeirão Preto, SP, Brazil). The superficial layer of infected dentin was selectively removed from the walls of the cavity. The affected dentine that was firm, resistant to curettage, and close to the pulp is subject to remineralization [22–24] and was maintained. The selective removal of carious tissue followed the established clinical hardness criteria [25].

2.7. Microbiological analysis of dentin scrapings (after caries removal)

A sample of demineralized dentin from the pulp wall was collected with sterile curettes # 11, # 11½, and # 12 and weighed (3 mg) for microbiological analysis.

2.8. Treatment with aPDT

Antimicrobial photodynamic therapy (aPDT) was performed in selected teeth (n = 20), after selective caries removal, using InGaAlP laser (TF Premier-MM Optics) with the following specifications: 660 nm wavelength, red light spectrum region, 100 mW power, 640 J/cm^2 energy density, for 180 s, associated with 0.005% methylene blue photosensitizer. The pre-irradiation time was 5 min [16,26]. Afterwards, the teeth were washed abundantly with water for 1 min.

2.9. Microbiological analysis of caries lesion (after aPDT treatment)

The teeth treated with aPDT underwent a third collection of dentin scrapings (n = 10), with sterile curettes, following the protocol described previously in the post-removal phase.

2.10. Restorative treatment

Teeth received indirect pulp protection according to the depth of the cavities. In the deep cavities, calcium hydroxide cement (Dycal; Dentisply Indústria e Comércio Ltda, Petrópolis, RJ, Brazil) was used, followed by the application of glass ionomer cement (Ketac Molar; 3 M, São Paulo, Brazil). In medium cavities, only the glass ionomer cement (Ketac Molar; 3 M, São Paulo, Brazil) was used.

The dentin was etched with 37% phosphoric acid for 7 s and enamel for 15 s [27] followed by washing with water for 1 min. The excess water was removed with a suction cannula and the cavity was dried with cotton balls.

The adhesive system Adper Single Bond 2 (3 M ESPE, São Paulo, SP, Brazil) was applied in two layers with a disposable applicator (KGBrush, KG Sorensen, Cotia, SP, Brazil), interspersed with an air jet for 5 s, and light-cured (Gnatus, Ribeirão Preto, SP, Brazil), following the manufacturer's instructions. Then, the composite resin Z350 (3 M ESPE, São Paulo SP, Brazil) was applied in small increments with a resin spatula, light-cured for 20 s, reconstructing the crown of the primary molars. The rubber dam was removed, occlusal adjustment was performed with carbon paper (AccuFilm, Parkell, Farmingdale, NY, USA), and diamond burs were used for finishing (KG Sorensen, Cotia, SP, Brazil). After seven days, the children returned for final polishing of the restoration with abrasive burs (Enhance, Dentisply Indústria e Comércio Ltda., Petrópolis, RJ, Brazil).

2.11. Clinical evaluation of restorations

The teeth were carefully evaluated qualitatively at 7 days after the restoration (after polishing - baseline) and after 6 months. The evaluation was performed by two examiners following the modified USPHS criteria [28,29], which include the analysis of retention, marginal discoloration, secondary caries, marginal adaptation, and color. The restorations were classified into 3 categories: *Alpha* – absence of problems and restoration in perfect condition; *Bravo* – with small but clinically acceptable failures, and *Charlie* – with major failures and restoration needs replacement (Table 1).

2.12. Data analysis

Colony forming units (CFU/mg dentin) were calculated for each experimental condition and transformed to $\log_{10}$. Data analysis was done using Statistical Package for the Social Sciences version 23.0 (SPSS Inc., v23, Chicago, IL, USA) with a significance level of 5%. Shapiro-wilk was used to check normality of the distribution. Sphericity was tested with Mauchly's test. Repeated measures ANOVA was done using the Greenhouse-Geisser correction row. Post-hoc analysis was performed with Bonferroni test.

3. Results

Data were normally distributed for all groups (Shapiro-wilk test): before selective caries removal ($p = 0.3390$); after selective caries removal ($p = 0.3122$) and after the application of aPDT ($p = 0.0648$). As the assumption of sphericity was not satisfied ($p < 0.05$), the Greenhouse-Geisser test was used for adjustments. The one-way ANOVA with repeated measures showed that there is an effect of the caries lesion treatment factor on microorganisms [F (1,240, 9,921) = 12,460; $p = 0.004$].

The Bonferroni post-hoc test showed significant difference between

Table 1
Modified USPHS criteria employed during the evaluation of restorations.

Category	Score	Criteria
Retention	*Alpha*	Without loss of restorative material
	Charlie	With loss of restorative material
Marginal discoloration	*Alpha*	Without marginal discoloration
	Bravo	Slight marginal discoloration, without axial penetration
	Charlie	Marginal discoloration with axial penetration
	Alpha	Perfectly adapted, without visible edges
Marginal adaptation	*Bravo*	Visible edge, but clinically acceptable
	Charlie	Marginal leakage, clinical failure.
Color	*Alpha*	No color disharmony and/or translucency between the restoration and the tooth
	Bravo	Disharmony between the restoration and the tooth within acceptable limits of color, hue and/or translucency.
	Charlie	Disharmony between the restoration and the tooth outside the acceptable limits of color, hue and/or translucency – aesthetically unpleasant.
Secondary caries	*Alpha*	No recurrence of caries
	Charlie	With recurrence of caries

Table 2
Mean (standard deviation) of *S mutans* found in dentin at different periods.

Periods	*Streptococcus mutans* (CFU/mg dentin in $\log_{10}$)
Before selective caries removal	5.51 (0.84) [A]
After selective caries removal	4.59 (1.13) [B]
After application of antimicrobial photodynamic therapy (aPDT)	2.71 (2.24) [C]

Distinct letters indicate significant differences among treatments/groups ($p < 0.05$).

treatments ($p < 0.05$). There was a significant reduction in the amount of microorganisms after selective caries removal ($p = 0.04$) and also after the application of aPDT ($p = 0.01$). The reduction of *S. mutans* CFU was of 76.4% after caries removal; and after caries removal associated with aPDT, the reduction was of 92.6%. Table 2 shows the amount of *S. mutans* found in dentin at different periods.

The effect of aPDT on composite resin restorations was not relevant in this study. No difference was found between the teeth that received the aPDT and those that did not receive it for all the evaluated criteria: retention, marginal adaptation, marginal discoloration, secondary caries, and color. In the 6 months analysis, an inadequate marginal adaptation was observed in 2 restorations, one in each treatment group, as observed in Chart 1 . Fig. 2 and 3 show representative photographs of treatments.

4. Discussion

Conservative or ultraconservative removal of carious tissue has been proposed for the maximal preservation of dental tissue with bacterial reduction after a certain time and the possibility of remineralization of the affected dentin [30,31]. However, despite the benefits of selective caries removal, microorganisms remain in the affected dentin after conservative treatment. Steiner-Oliveira [16] reported that aPDT might be a promising alternative for elimination of these microorganisms increasing the chances of a successful treatment. Moreover, the literature reports that aPDT application has been recently expanded to dentistry and it has received renewed attention in the context of dental caries management [32,33].

The selective removal of caries affects the lesion's microenvironment, decreasing the bacterial diversity, which arrests lesion progression, reduces the risk of pulp exposure [34], and preserves pulp vitality [35]. Another advantage of the conservative treatment is that the primary tooth might be maintained until its natural exfoliation [36], which is important for the oral health of children [37]. For these reasons, the selective removal was recommended for the children of the present study.

The null hypothesis regarding the reduction of microorganisms was rejected. The results showed that the InGaAlP laser associated with 0.005% methylene blue photosensitizer significantly reduced *S. mutans* after selective caries removal. The present findings showed that selective removal of carious tissue reduced 76.4% of *S. mutans*. With the application of aPDT, a total reduction of 92.6% was observed, proving that aPDT is a viable technique for the removal of microorganisms, increasing the chances of a successful treatment. Therefore, despite the effectiveness of selective caries removal, microorganisms were found in the remaining dentin but were reduced with aPDT. It should be noted that in 40% of the patients there was total elimination of *S. mutans* after application of aPDT.

Factors such as type and concentration of photosensitizer, wavelength adapted to the photosensitizer, irradiation time, and applied energy factors are factors indispensable for a successful treatment using aPDT [38]. However, the variety of laser or LED light protocols and the few studies evaluating the properties of available dyes and light sources makes comparisons difficult [39]. In this study, we treated carious

Treatment	Retention			Marginal Discoloration			Marginal Adaptation			Color			Secondary Caries		
	*A	B	C	A	B	C	A	B	C	A	B	C	A	B	C
With aPDT															
Baseline	20 (100%)	0 (0%)	0 (0%)	20 (100%)	0 (0%)	0 (0%)	20 (100%)	0 (0%)	0 (0%)	20 (100%)	0 (0%)	0 (0%)	20 (100%)	0 (0%)	0 (0%)
6 months	20 (100%)	0 (0%)	0 (0%)	20 (100%)	0 (0%)	0 (0%)	19 (95%)	1 (5%)	0 (0%)	20 (100%)	0 (0%)	0 (0%)	20 (100%)	0 (0%)	0 (0%)
Without aPDT															
Baseline	20 (100%)	0 (0%)	0 (0%)	20 (100%)	0 (0%)	0 (0%)	20 (100%)	0 (0%)	0 (0%)	20 (100%)	0 (0%)	0 (0%)	20 (100%)	0 (0%)	0 (0%)
6 months	20 (100%)	0 (0%)	0 (0%)	20 (100%)	0 (0%)	0 (0%)	19 (95%)	1 (5%)	0 (0%)	20 (100%)	0 (0%)	0 (0%)	20 (100%)	0 (0%)	0 (0%)

Chart 1. Results of the clinical analysis of the class I restorations using modified USPHS criteria.

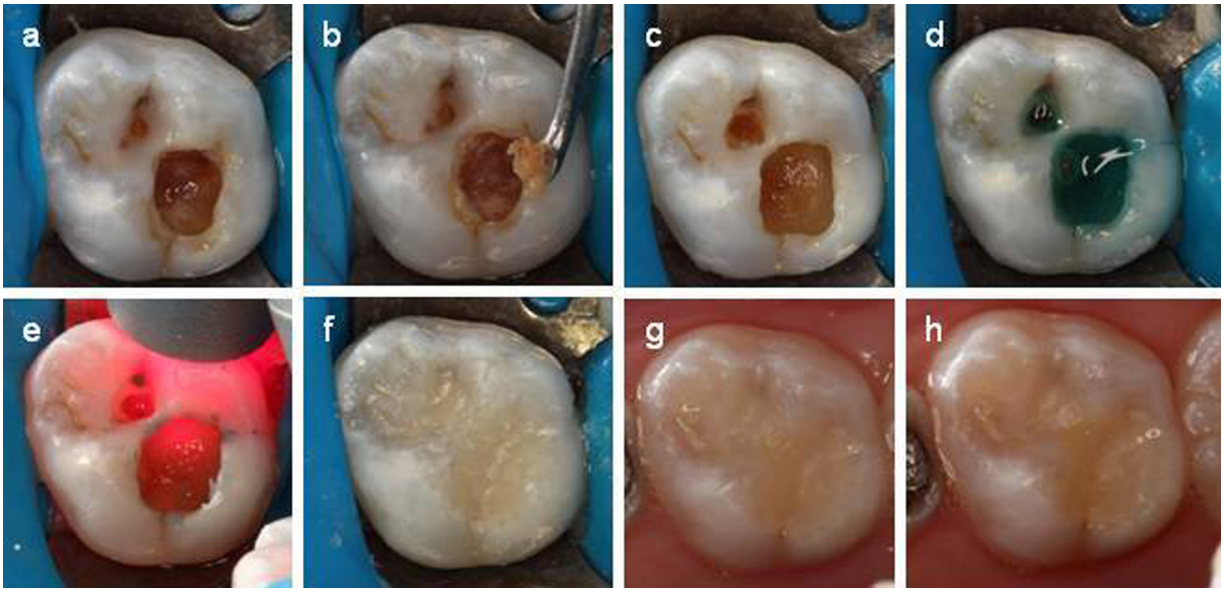

Fig. 2. Treatment of affected dentin with aPDT. *a*: active caries lesion on the occlusal surface of primary molar; *b*: selective removal of caries tissue; *c*: cavity appearance after selective removal of caries tissue; *d*: application of methylene blue photosensitizer; *e*: InGaAlP laser application; *f*: aspect of restoration immediately after its accomplishment; *g*: restoration after polishing (baseline); *h*: aspect of restoration after 6 months.

lesion with an indium gallium aluminum phosphide diode laser prototype, termed low-level laser therapy [40] at a high dosimetry of 640 J/cm^2 [38] combined with the 0.005% methylene blue [41]. Unlike, Neves [42] used InGaAlP diode laser with 0.01% methylene blue at a dosimetry of 120 J/cm^2 and 40 mW but concluded that this treatment was not a viable clinical alternative to reduce bacterial contamination in deep dentin. Laser radiation in the red visible and near infrared region is able to pass through demineralized dentin. However, in spite of being able to act effectively to reach micro-organisms enmeshed in dentin [43], it has been previously demonstrated that bacterial death is lower when the microorganisms are irradiated with light passing through demineralized dentin slices [44]. This means that higher irradiances are required to exert the same destructive effect than when the microorganisms are on the surface, such as the use of higher power diode [43]. Therefore, in the present study, the use of a protocol with increased power and energy density may have been an interesting alternative to improve the results [26].

Another important consideration is about the concentrations of photosensitizers used. It is known that dyes in high concentrations can induce the self-quenching phenomenon, reducing the amount of light that actually reaches the bacteria and generating reactive oxygen species which could interfere in the effectiveness of aPDT [26]. Therefore, it can be assumed that lower concentrations of photosensitizers would provide better results, as was suggested by Gugliemi [26] and was verified in the present study, where positive results were found for the reduction of *S. mutans* through the use of the 0.005% methylene blue

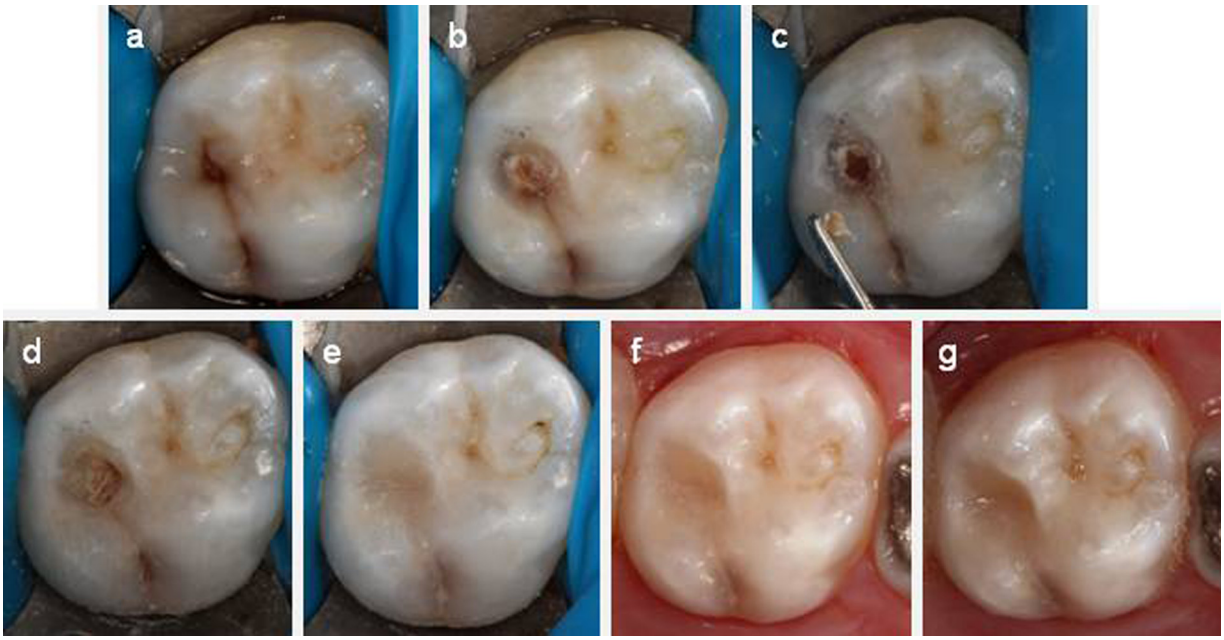

Fig. 3. Tooth not submitted to aPDT treatment. *a*: active caries lesion on the occlusal surface of primary molar; *b*: access to caries lesion through the removal of superficial enamel; *c*: selective removal of caries tissue; *d*: cavity appearance after selective removal of caries tissue; *e*: aspect of restoration immediately after its accomplishment; *f*: restoration after polishing (baseline); *g*: aspect of restoration after 6 months.

photosensitizer. Methylene blue, even at lower concentration, can efficiently penetrate the cell walls of negatively charged microorganisms, improving the action of aPDT [41].

Regarding restorations, the null hypothesis was accepted, as aPDT did not affect the quality of the resin restorations. There were two restorations that were classified as *Bravo* for marginal adaptation after 6 months; however, the samples were one from each group, not allowing any conclusion about the influence of aPDT in this result. Different concentrations of methylene blue photosensitizer do not appear to influence the quality of the restorations. Studies using 0.01% methylene blue [45] had excellent results regarding marginal adaptation similarly to the present study that used a 0.005% concentration.

The generation of free oxygen species has been a concern regarding the interference of oxygen radicals with the bonding process and formation of resin tags at the tooth-adhesive interface, considering that oxygen free radicals may react with the adhesive solvent (acetone or alcohol) and adversely affect the quality of marginal seal. However, the literature reports that aPDT using methylene blue promotes an amount of oxygen in photosensitizer too low to interfere with the polymerization process and thus, it do not increase the microleakage. Therefore, it is considered that aPDT is safe for disinfection of cavities [46], and it can be affirmed that it does not promote alterations related to marginal adaptation and secondary caries, which were also evaluated in the present study, and good results were obtained.

Methylene blue has the highest molecular weight (375.91 g/mol) which makes difficulty its penetration through the dental canaliculi [47]. This may causes less color change [48], as confirmed in a previous study [46]. This fact may explain why this dye did not promote alterations related to marginal discoloration of the restorations in the present study.

Regarding limitations found in this study, for being a clinical study, the return visits was complicating factor, since patients had already received the aesthetic and restorative treatment they needed. In addition, we lost some patients because they had been changed addresses, and could not be found. During the treatments, the collected dentin had to be placed in the microtubes containing 0.9% NaCl solution to avoid the dryness of the dentin and to keep microorganisms preserved. The literature presents several studies [49–51] that confirm the high evaporation rate of the NaCl solution which can lead to mistakes during weighing. To correct this method, the empty microtubes were previously weighed. Then, dentin was collected, weighed, and immediately after weighing, 1 mL of 0.9% NaCl solution was deposited inside the microtubes. This avoided the dryness of the dentin and the study was successfully conducted.

The results obtained in this study were promising in relation to the reduction of *S. mutans* and in the longitudinal behavior of restorations. The aPDT can be considered is an alternative for the selective caries removal, contributing to the reduction of microorganisms without interfering with the success of the restoration.

Conflict of interest

All authors declares no conflict of interest.

Ethical approval

This study was approved by the Research Ethics Committee of the Ribeirao Preto School of Dentistry, University of São Paulo (FORP / USP Case No 61188916.8.0000.5419). All procedures performed in studies involving human participants were in accordance with the ethical standards of the institutional and/or national research committee and with the 1964 Helsinki declaration and its later amendments or comparable ethical standards.

Informed consent

Informed consent was obtained from all individual participants included in the study.

Acknowledgment

The first author would like to thank the São Paulo Research Foundation (FAPESP) for financial support (grant #2016/21030-3).

References

[1] R.P. Allaker, C.W. Douglas, Novel anti-microbial therapies for dental plaque-related diseases, Int. J. Antimicrob. Agents 33 (2009) 8–13, https://doi.org/10.1016/j.ijantimicag.2008.07.014.
[2] S. Wood, D. Metcalf, D. Devine, C. Robinson, Erythrosine is a potential photosensitizer for the photodynamic therapy of oral plaque biofilms, J. Antimicrob. Chemother. 57 (2006) 680–684, https://doi.org/10.1093/jac/dkl021.
[3] A. Azizi, S. Aghayan, S. Zaker, M. Shakeri, N. Entezari, S. Lawaf, In vitro effect of zingiber officinale extract on growth of streptococcus mutans and streptococcus sanguinis, Int. J. Dent. (2015) 1–21, https://doi.org/10.1155/2015/489842 489842.
[4] S.R. Wood, J. Kirkham, P.D. Marsh, R.C. Shore, B. Nattress, C. Robinson, Architecture of intact natural human plaque biofilms studied by confocal laser scanning microscopy, J. Dent. Res. 79 (2000) 21–27, https://doi.org/10.1177/00220345000790010201.
[5] J.A. Cury, M.A. Rebello, A.A. Del Bel Cury, In situ relationship between sucrose exposure and the composition of dental plaque, Caries Res. 31 (1997) 356–360, https://doi.org/10.1159/000262418.
[6] J.A. Cury, M.A. Rebelo, A.A. Del Bel Cury, M.T. Derbyshire, C.P. Tabchoury, Biochemical composition and cariogenicity of dental plaque formed in the presence of sucrose or glucose and fructose, Caries Res. 34 (2000) 491–497, https://doi.org/10.1159/000016629.
[7] M. Nobre dos Santos, L. Melo dos Santos, S.B. Francisco, J.A. Cury, Relationship among dental plaque composition, daily sugar exposure and caries in the primary dentition, Caries Res. 36 (2002) 347–352, https://doi.org/10.1159/000065959.
[8] G.H. Dibdin, R.P. Shellis, Physical and biochemical studies of Streptococcus mutans sediments suggest new factors linking the cariogenicity of plaque with its extracellular polysaccharide content, J. Dent. Res. 67 (1988) 890–895, https://doi.org/10.1177/00220345880670060101.
[9] M. Busuioc, K. Mackiewicz, B.A. Buttaro, P.J. Piggot, Role of intracellular polysaccharide in persistence of Streptococcus mutans, J. Bacteriol. 191 (2009) 7315–7322, https://doi.org/10.1128/JB.00425-09.
[10] M.M. Jingarwar, N.K. Bajwa, A. Pathak, Minimal intervention dentistry—a new frontier in clinical dentistry, J. Clin. Diagn. Res. 8 (2014) 4–8, https://doi.org/10.7860/JCDR/2014/9128.4583.
[11] J.M. Ferreira, S.L. Pinheiro, F.C. Sampaio, V.A. de Menezes, Caries removal in primary teeth—a systematic review, Quintessence Int. 43 (2012) 9–15.
[12] C.C. Ribeiro, E.C. de Oliveira Lula, R.C. da Costa, A.M. Nunes, Rationale for the partial removal of carious tissue in primary teeth, Pediatr. Dent. 34 (2012) 39–41.
[13] F. Cieplik, W. Buchalla, E. Hellwigb, A. Al-Ahmabd, K.A. Hiller, T. Maischc, L. Karygiannib, Antimicrobial photodynamic therapy as an adjunct for treatment of deep carious lesions—a systematic review, Photodiagn. Photodyn. Ther. 18 (2017) 54–62, https://doi.org/10.1016/j.pdpdt.2017.01.005.
[14] D.S. Wambier, F.A. Dos Santos, A.C. Guedes-Pinto, R.G. Jaeger, M.R. Simionato, Ultrastructural and microbiological analysis of the dentin layers affected by caries lesions in primary molars treated by minimal intervention, Pediatr. Dent. 29 (2007) 228–234.
[15] S.L. Pinheiro, A.A. Schenka, A.A. Neto, C.P. de Souza, H.M. Rodriguez, M.C. Ribeiro, Photodynamic therapy in endodontic treatment of deciduous teeth, Lasers Med. Sci. 24 (2009) 521–526, https://doi.org/10.1007/s10103-008-0562-2.
[16] C. Steiner-Oliveira, P.L. Longo, A.C. Aranha, K.M. Ramalho, M.P. Mayer, C. de Paula Eduardo, Randomized in vivo evaluation of photodynamic antimicrobial chemotherapy on deciduous carious dentin, J. Biomed. Opt. 20 (10) (2015), https://doi.org/10.1117/1.JBO.20.10.108003.
[17] M. Wilson, J. Dobson, W. Harvey, Sensitization of oral bacteria to killing bylow-power laser radiation, Curr. Microbiol. 25 (1992) 77–81.
[18] A. Arash, S. Samira, R. Maryam, R. Arash, L. Shirin, Effect of photodynamic therapy with two photosensitizers on Streptococcus mutants: in vitro study, Photodiagn. Photodyn. Ther. 16 (2016) 66–71, https://doi.org/10.1016/j.pdpdt.2016.08.002.
[19] A.C. da Mota, C.R. Leal, S. Olivan, M.L. Leal Gonçalves, V.A. de Oliveira, M.M. Pinto, S.K. Bussadori, Case report of photodynamic therapy in the treatment of dental caries on primary teeth, Lasers Med. Sci. 7 (2016) 131–133, https://doi.org/10.15171/jlms.2016.22.
[20] P.V. Araújo, J.F. Correia-Silva, R.S. Gomez, M.L. Massara, M.E. Cortes, L.T. Poletto, Antimicrobial effect of photodynamic therapy in carious lesions in vivo, using culture and real-time PCR methods, Photodiagn. Photodyn. Ther. 12 (2015) 401–407, https://doi.org/10.1016/j.pdpdt.2015.06.003.
[21] K.F. Schulz, D.G. Altman, D. Moher, Group CONSORT, CONSORT 2010 statement: updated guidelines for reporting parallel group randomized trials, Ann. Intern. Med. 152 (2010) 726–732, https://doi.org/10.7326/0003-4819-152-11-201006010-00232.

[22] E.A. Kidd, How clean must a cavity be before restoration? Caries Res. 38 (2004) 305–313, https://doi.org/10.1159/000077770.
[23] M. Maltz, J.J. Jardim, H.D. Mestrinho, P.M. Yamaguti, K. Podestá, M.S. Moura, L.M. de Paula, Partial removal of carious dentine: a multicenter randomized controlled trial and 18-month follow-up results, Caries Res. 47 (2013) 103–109, https://doi.org/10.1159/000344013.
[24] V. Thompson, R.G. Craig, F.A. Curro, W.S. Green, J.A. Ship, Treatment of deep carious lesions by complete excavation or partial removal: a critical review, J. Am. Dent. Assoc. 139 (2008) 705–712, https://doi.org/10.14219/jada.archive.2008.0252.
[25] M. Maltz, E.F. Oliveira, V. Fontanella, G. Carminatti, Deep caries lesions after incomplete dentine caries removal: 40-month follow-up study, Caries Res. 41 (2007) 493–496, https://doi.org/10.1159/000109349.
[26] C.A. Guglielmi, M.R. Simionato, K.M. Ramalho, J.C. Imparato, S.L. Pinheiro, M.A. Luz, Clinical use of photodynamic antimicrobial chemotherapy for the treatment of deep carious lesions, J. Biomed. Opt. 16 (2011) 088003, https://doi.org/10.1117/1.3611009.
[27] B. Van Meerbeek, M. Peumans, M. Verschueren, S. Gladys, M. Braem, P. Lambrechts, G. Vanherle, Clinical status of ten dentin adhesive systems, J. Dent. Res. 73 (1994) 1690–11702, https://doi.org/10.1177/00220345940730110401.
[28] J.F. Cvar, G. Ryge, Reprint of criteria for the clinical evaluation of dental restorative materials, Clin. Oral Investig. 9 (2005) 215–1232, https://doi.org/10.1007/s00784-005-0018-z.
[29] R.M. Vieira, A.S. Camargo, L. Irgang, M.C.G. Erhardt, F.F. Demarco, F.H. Coelho-De-Souza, Retrospective clinical assessment of composite resin cervical restorations, RFO UPF 18 (2013) 335–344.
[30] A.I. Orhan, F.T. Oz, B. Ozcelik, K. Orhan, A clinical and microbiologicalcomparative study of deep carious lesion treatment in deciduous and youngpermanent molars, Clin. Oral Investig. 12 (2008) 369–378, https://doi.org/10.1007/s00784-008-0208-6.
[31] M. Hayashi, M. Fujitani, C. Yamaki, Y. Momoi, Ways of enhancing pulp preservation by stepwise excavation—a systematic review, J. Dent. 39 (2011) 95–107, https://doi.org/10.1016/j.jdent.2010.10.012.
[32] G.C. Santin, D.S. Oliveira, R. Galo, M.C. Borsatto, S.A. Corona, Antimicrobial photodynamic therapy and dental plaque: a systematic review of the literature, Sci. World J. 2014 (2014) 824538, https://doi.org/10.1155/2014/824538.
[33] H. Gursoy, C. Ozcakir-Tomruk, J. Tanalp, S. Yilmaz, Photodynamic therapy in dentistry: a literature review, Clin. Oral Investig. 17 (2013) 1113–1125, https://doi.org/10.1007/s00784-012-0845-7.
[34] D. Ricketts, T. Lamont, N.P. Innes, E. Kidd, J.E. Clarkson, Operative caries management in adults and children, Cochrane Database Syst. Rev. (2013), https://doi.org/10.1002/14651858.CD003808.pub3 CD003808.
[35] R. Brignardello-Petersen, Stepwise and partial caries removal probably have high success rates up to 3 years after treatment of deep carious lesions, but partial caries removal is more likely to preserve tooth vitality, J. Am. Dent. Assoc. 148 (2017) e38, https://doi.org/10.1016/j.adaj.2017.02.012.
[36] N.P. Innes, D.J. Evans, Modern approaches to caries management of the primary dentition, Br. Dent. J. 214 (2013) 559–566, https://doi.org/10.1038/sj.bdj.2013.529.
[37] T.C. Stafuzza, L.L.R. Vitor, D. Rios, T. Cruvinel Silva, M.A.M. Machado, T.M. Oliveira, Clinical and radiographic success of selective caries removal to firm dentin in primary teeth: 18-month follow-up, Case Rep. Dent. (2018), https://doi.org/10.1155/2018/9213681 9213681.
[38] S.S. de Sousa Farias, M.A. Nemezio, S.A. Corona, C.P. Aires, M.C. Borsatto, Effects of low-level laser therapy combined with toluidine blue on polysaccharides and biofilm of Streptococcus mutans, Lasers Med. Sci. 31 (2016) 1011–1016, https://doi.org/10.1007/s10103-016-1944-5.
[39] J.Y. Nagata, N. Hioka, E. Kimura, V.R. Batistela, R.S. Terada, A.X. Graciano, M.L. Baesso, M.F. Hayacibara, Antibacterial photodynamic therapy for dental caries: evaluation of the photosensitizers used and light source properties, Photodiagn. Photodyn. Ther. 9 (2012) 122–131, https://doi.org/10.1016/j.pdpdt.2011.11.006.
[40] L.J. Walsh, The current status of low level laser therapy in dentistry. Part 1. Soft tissue applications, Aust. Dent. 42 (1997) 247–254.
[41] F.L. Esban Florez, M.R. Mendonça de Oliveira, O.B. de Oliveira Junior, R.D. Hiers, S.S. Khajotia, P. Pretel, Bioluminescence analysis of antibacterial photodynamic therapy using methylene blue mediated by low-intensity level laser against cariogenic biofilms, Photomed. Laser Surg. 36 (2018) 258–265, https://doi.org/10.1089/pho.2017.4326.
[42] P.A. Neves, L.A. Lima, F.C. Rodrigues, T.J. Leitão, C.C. Ribeiro, Clinical effect of photodynamic therapy on primary carious dentin after partial caries removal, Braz. Oral Res. 30 (2016) 47–54, https://doi.org/10.1590/1807-3107BOR-2016.vol30.0047.
[43] L.J. Walsh, The current status of low level laser therapy in dentistry. Part 2. Hard tissue applications, Aust. Dent. 42 (1997) 302–306.
[44] T. Burns, M. Wilson, G.J. Pearson, Effect of dentine and collagen on the lethal photosensitization of Streptococcus mutans, Caries Res. 29 (1995) 192–197, https://doi.org/10.1159/000262068.
[45] E.V. de Araújo Neto Jr., R. de Albuquerque Dias, Use of antimicrobial photodynamic therapy in the conservative clinical management of caries lesions on a permanent tooth, Photodiagn. Photodyn. Ther. 20 (2017) 207–209, https://doi.org/10.1016/j.pdpdt.2017.09.014.
[46] L. Madani, E. Sarkisians, N. Kiomarsi, M.J. Kharazifard, N. Chiniforush, Effect of antimicrobial photodynamic therapy on microleakage of class cavities restored with composite resin, Photodiagn. Photodyn. Ther. 23 (2018) 78–82, https://doi.org/10.1016/j.pdpdt.2018.06.010.
[47] L.M. Costa, F.S. Matos, A.M. Correia, N.C. Carvalho, A.L. Faria-E-Silva, L.R. Paranhos, M.A. Ribeiro, Tooth color change caused by photosensitizers after photodynamic therapy: an in vitro study, J. Photochem. Photobiol. B 160 (2016) 225–228, https://doi.org/10.1016/j.jphotobiol.2016.04.019.
[48] R.A. Figueiredo, L.C. Anami, I. Mello, E.S. Carvalho, S.M. Habitante, D.P. Raldi, Tooth discoloration induced by endodontic phenothiazine dyes in photodynamic therapy, Photomed. Laser Surg. 32 (2014) 458–462, https://doi.org/10.1089/pho.2014.3722.
[49] N.A. Combe, D.J. Donaldson, Water evaporation from acoustically levitated aqueous solution droplets, J. Phys. Chem. A 121 (2017) 7197–7204, https://doi.org/10.1021/acs.jpca.7b08050.
[50] T.K. Pradhan, P.K. Panigrahi, Convection inside condensing and evaporating droplets of aqueous solution, Soft Matter 14 (2018) 4335–4343, https://doi.org/10.1039/c8sm00205c.
[51] V. Soulié, S. Karpitschka, F. Lequien, P. Prené, T. Zemb, H. Moehwald, H. Riegler, The evaporation behavior of sessile droplets from aqueous saline solutions, Phys. Chem. Chem. Phys. 17 (2015) 22296–22303, https://doi.org/10.1039/c5cp02444g.